



## Review

Endofibrosis and Kinking of the Iliac Arteries in Athletes: A Systematic Review **CME**G. Peach<sup>a</sup>, G. Schep<sup>b</sup>, R. Palfreeman<sup>c</sup>, J.D. Beard<sup>d</sup>, M.M. Thompson<sup>a</sup>, R.J. Hinchliffe<sup>a,\*</sup><sup>a</sup> St George's Vascular Institute, 4th Floor, St James Wing, St George's Healthcare NHS Trust, Blackshaw Rd, London SW17 0QT, UK<sup>b</sup> Department of Sports Medicine, Maxima Medical Centre, Veldhoven, The Netherlands<sup>c</sup> Claremont Sports Medicine and Performance Centre, Sheffield, UK<sup>d</sup> Sheffield Vascular Institute, University of Sheffield, Regent Court, 30 Regent St, Sheffield S1 4DA, UK

## ARTICLE INFO

## Article history:

Received 19 May 2011

Accepted 28 November 2011

Available online 19 December 2011

## Keywords:

Iliac artery  
Endofibrosis  
Kinking  
Sport  
Cyclist

## ABSTRACT

**Introduction:** Kinking and endofibrosis of the iliac arteries are uncommon and poorly recognized conditions affecting young endurance athletes. Deformation or progressive stenosis of the iliac artery may reduce blood flow to the lower limb and adversely affect performance. The aim of this review was to examine the existing literature relating to these flow-limiting phenomena and identify a clear, unifying strategy for the assessment and management of affected patients.

**Methods:** A systematic review of the literature was performed. A comprehensive search was carried out using Medline, Embase and The Cochrane Database to identify relevant articles published between 1950 and 2011 (last search date 05/08/2011). This search (and additional bibliography review) identified 413 articles, of which 367 were excluded. 46 articles were then studied in detail. Methodological quality of studies was assessed according to Scottish Intercollegiate Guideline Network criteria.

**Results:** Focussed history and examination can successfully identify nearly 80% of patients with iliac flow limitation. However, both provocative exercise tests and detailed imaging are also necessary to identify those in need of intervention and establish most appropriate treatment. Provocative exercise tests and duplex imaging can then be used to confirm flow limitation before detailed assessment of abnormal anatomy with MRA and DSA. These multiple imaging modalities are necessary to identify those most likely to benefit from surgery and clarify whether each patient should undergo arterial release, vessel shortening, endofibrosectomy or interposition grafting.

**Conclusion:** We present a systematic review of the literature together with a proposed algorithm for diagnosis and management of these iliac flow limitations in endurance athletes.

© 2011 European Society for Vascular Surgery. Published by Elsevier Ltd. All rights reserved.

## Introduction

The onset of exercise-induced leg pain in young, otherwise healthy individuals can often lead to diagnostic difficulty, particularly when those affected are high-performance athletes. Since this group is inevitably exposed to the risk of physical injury during training or competition, such symptoms are commonly attributed to musculoskeletal causes. It is often only when symptoms fail to resolve despite standard physiotherapy regimens that other potential causes are sought.

The possibility that these symptoms could be caused by non-atherosclerotic arterial insufficiency was first suggested more

than two decades ago.<sup>1,2</sup> Despite having no cardiovascular risk factors, highly trained young athletes were found to have localized flow limitation within the iliac arteries. Vessel stenosis was often caused by endofibrosis – a pathological thickening of the vessel intima – or kinking of the iliac artery. However, the number of clearly identified cases of endofibrosis or iliac kinking has remained relatively low – possibly as a result of low awareness of these conditions or due to discrepancies in diagnostic criteria and difficulties in establishing a reliable, reproducible imaging modality.

This review assesses the existing literature on endofibrosis and kinking of the iliac arteries and presents evidence for the aetiology, diagnosis and management of these conditions.

## Methods

A comprehensive literature search was performed using Medline, Embase, and The Cochrane Database to identify relevant

**CME** To access continuing medical education questions on this paper, please go to [www.vasculeducation.com](http://www.vasculeducation.com) and click on 'CME'

\* Corresponding author. Tel.: +44(0)2087255939, +44 07733205706; fax: +44 (0) 2087253295.

E-mail address: [rhinchli@sgul.ac.uk](mailto:rhinchli@sgul.ac.uk) (R.J. Hinchliffe).

articles published between 1950 and 2011 (last search date 05/08/2011). The following search string was used:

[(“endofibrosis” OR “fibrosis” OR “arteriopathy” OR “syndrome” OR “flow”).ti,ab OR exp FIBROSIS/ AND (“iliac art\*” OR “iliac”).ti,ab OR ILIAC ARTERY/] AND [(athlet\* OR runn\* OR sport\* OR cycl\* OR bicycl\*).ti,ab OR exp SPORTS/ OR exp RUNNING/ OR EXP ATHLETICS/]

Published studies describing pathology, symptoms, diagnosis or management of iliac endofibrosis or iliac artery kinking were considered for inclusion. References of the included papers were also searched to identify any other articles of relevance. No language restriction was made. Review articles were subsequently excluded.

Due to the nature of the papers included there was insufficient homogeneous data to allow meta-analysis. A systematic review was therefore undertaken following PRISMA guidelines.<sup>3</sup> The quality of diagnostic and observational studies was assessed using the QUADAS and STROBE tools<sup>4,5</sup> and evidence graded according to SIGN guidelines:<sup>6</sup>

#### SIGN levels of evidence

- 1++ High quality meta-analyses, systematic reviews of RCTs or RCTs with a very low risk of bias
- 1+ Well-conducted meta-analyses, systematic reviews, or RCTs with a low risk of bias
- 1– Meta-analyses, systematic reviews, or RCTs with a high risk of bias

- 2++ High quality systematic reviews of case control or cohort studies or high quality case control or cohort studies with a very low risk of confounding or bias and a high probability that the relationship is causal.
- 2+ Well conducted case control or cohort studies with a low risk of confounding or bias and a moderate probability that the relationship is causal
- 2– Case control or cohort studies with a high risk of confounding or bias and a significant risk that the relationship is not causal
- 3 Non-analytic studies, e.g. case reports, case series
- 4 Expert opinion.

#### Results

407 articles were identified using the above search strategy. Title/abstract review resulted in the exclusion of 339 articles that were not directly relevant. Detailed assessment of the remaining studies resulted in exclusion of a further 28. Review of bibliographies identified another 6 relevant studies for inclusion. 46 articles were therefore assessed in detail (Fig. 1). Though many of these were case reports or very small case series, 17 studies evaluated more than 5 symptomatic limbs (Table 1).

Quality assessment demonstrated that the majority of these studies offer only intermediate-level evidence, with none of the diagnostic studies achieving a SIGN level greater than 2+.<sup>6</sup> In

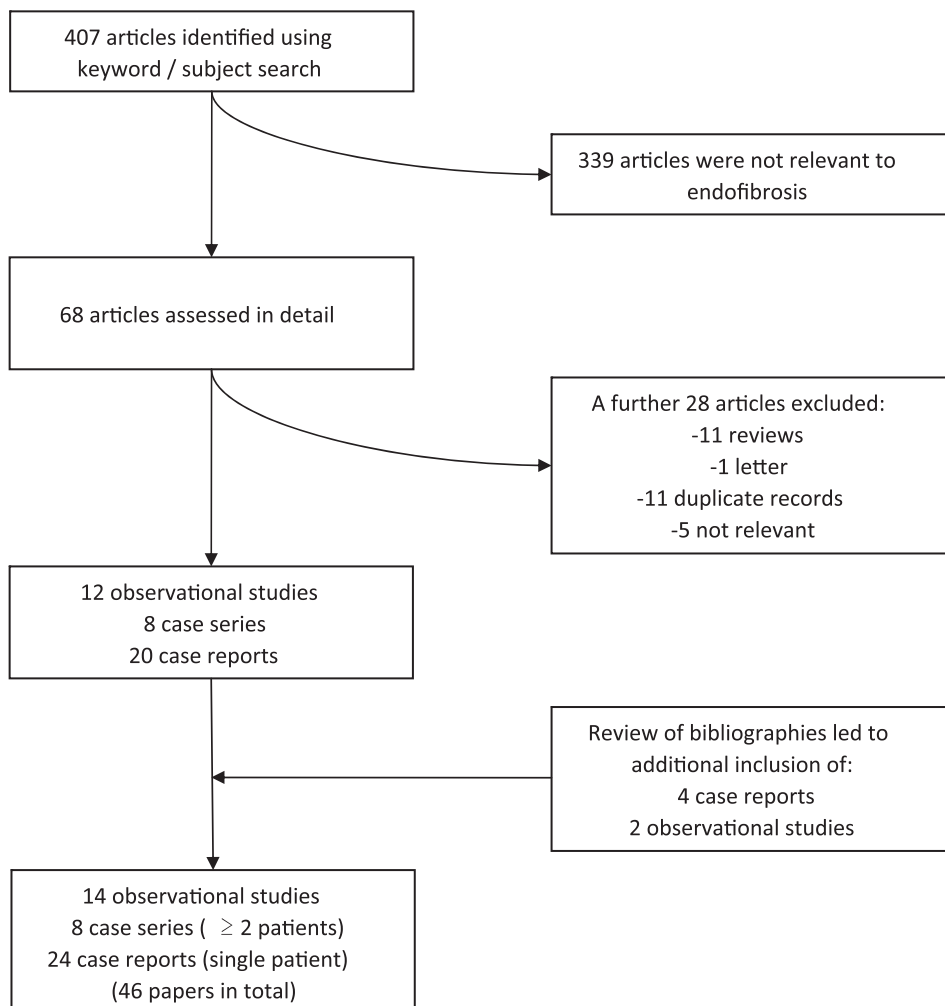


Figure 1. PRISMA flow diagram representing the performed literature search.

**Table 1**  
Characteristics of all studies assessing >5 affected limbs.

Author	Year	Study type	No. of symptomatic athletes (limbs)	No of asymptomatic athletes (limbs)	Focus of study	SIGN level of evidence	Reference
<i>Pathology</i>							
Schep	2002	Case-control	43(46)	16(32)	Iliac length	2+	20
Schep <sup>a</sup>	2001	Case-control	42(46)	16(32)	Iliac length	2+	38
Schep	2001	Case-control	50(55)	16(32)	Iliac kinking	2+	39
Vink	2008	Case-control	18(19)	22(42) <sup>a</sup>	Histology	2++	27
<i>Diagnosis</i>							
Schep	2002	Diagnostic	80(92)	35(70)	History/physical exam	2+	24
Abraham	2001	Diagnostic	78(–)	108(216)	ABPI	2+	50
Bruneau	2009	Diagnostic	22(22)	53(53)	ABPI	2–	47
Le Faucher	2006	Diagnostic	42(42)	42(84)	ABPI	2+	48
Fernandez-Garcia	2002	Diagnostic	7(7)	11(22)	ABPI	2–	49
Taylor	2001	Diagnostic	12	20	ABPI	2+	51
Alimi <sup>a</sup>	2004	Diagnostic	13(14)	0	USS/DSA	2+	23
Schep	2002	Diagnostic	80(92)	0	ABPI/USS	2+	28
Abraham	1993	Diagnostic	48(84)	0	USS	2+	52
Schep <sup>a</sup>	2001	Diagnostic	42(46)	16(32)	MRA	2–	38
<i>Treatment</i>							
Alimi <sup>a</sup>	2004	Case series	13(14)	0	Surgical repair	3	23
Feugier	2004	Case series	3334(350)	0	Histology/Surgical repair	3	22
Rousselet	1990	Case series	23(24)	0	Surgical repair	3	25
Schep	2002	Case series	24(24)	0	Surgical repair	3	45
Smith	2008	Case series	4(6)	0	Surgical repair	3	37

<sup>a</sup> Studies falling into more than one category (e.g. Diagnosis and Treatment), where level of evidence given relates to that particular aspect of the study.

general, the failure to achieve a higher level of evidence was due to the fact that there is no recognized gold standard of imaging against which diagnostic tests could be evaluated. Therefore, formal confirmation of the diagnosis (i.e. abnormal anatomy or histology) was only possible in those patients who tested positive on initial investigation and went on to have intervention. The reported diagnostic accuracy of each investigation should therefore be viewed with some caution.

All therapeutic studies were case series rather than randomized control trials and therefore achieved only level 3 evidence.<sup>6</sup> In each case details of follow-up were very limited, with clinical improvement generally used as the main marker of operative success rather than objective improvement in test results (such as ABPI). Where investigations were repeated postoperatively, there was no evidence that these tests were performed by independent observers. Nonetheless, the authors acknowledged the limitations of their studies and offer their findings as highly indicative rather than definitive.

## Epidemiology

Endofibrosis and iliac artery kinking have most often been described in competitive cyclists, ranging from serious amateur to professional. Nonetheless, endofibrosis has also been demonstrated in a number of other sports people, including speed skaters, endurance runners, triathletes, rugby players, soccer players, cross country skiers and body builders.<sup>7–21</sup>

Examining the characteristics of the presenting cyclists revealed that each had cycled an average of 120,000 km (range 30,000–500,000 km) prior to onset of symptoms. However, intensity of training may be at least as important as overall distance cycled in the genesis of the lesion, with those affected having cycled more than 14,500–20,000 km per year on average.<sup>22,23</sup>

The overall prevalence of iliac flow limitation amongst athletes has generally been hard to assess, since the condition may often go unrecognized and data remains sparse. However, Schep et al. have derived indirect evidence from their studies estimating prevalence to be as high as 10–20% amongst elite performance athletes.<sup>24</sup> Most reports describe patients of less than 40 yrs of age, but it has been

identified in subjects as old as 61.<sup>22</sup> The condition is also significantly more common in men, with, with less than 12% of affected individuals being female.<sup>20,22</sup> However, the apparently strong association with male gender may be somewhat biased by the greater number of men taking part in these endurance sports.

## Morphology

Iliac artery endofibrosis is a pathological process characterized by thickening of the vessel intima, causing progressive stenosis of the lumen and impaired flow. Whilst the lesion is invariably asymmetrical, it may be distributed circumferentially or eccentrically and possess multiple or single laminae. In some cases, the lesion may also be complicated by overlying thrombus, dissection, or atherosclerotic infiltration.<sup>25</sup> The arterial endothelium, media and adventitia are generally unaffected,<sup>1,25</sup> but there have been isolated reports of associated medial and adventitial hypertrophy.<sup>26</sup> In a series of 23 symptomatic cyclists who underwent operative intervention, stenoses were due to subendothelial accumulation of loose connective tissue containing variable amounts of collagen, elastin and smooth muscle cells.<sup>25</sup> Histology is quite distinct from atherosclerosis, where collagen fibres are densely packed and calcification is typically widespread.<sup>27</sup> Similarly patients with endofibrosis very rarely have any familial predisposition to cardiovascular disease.<sup>28</sup>

Endofibrosis has also been shown to be quite distinct from other stenotic conditions affecting young people. Though some morphological similarities to fibromuscular dysplasia (FMD) have been noted, FMD predominantly affects medial or adventitial layers and typically involves the renal or extracranial cerebrovascular arteries.<sup>29</sup> It is also clearly different from cystic adventitial disease, in which mucoid cysts develop within the adventitial layer of an artery (typically the popliteal), increasing adventitial thickness and compromising flow.<sup>30</sup>

In more than 90% of patients, endofibrosis affects the external iliac artery with the fibrotic segment generally measuring 2–6 cm in length.<sup>1,25,31</sup> In a small number of cases it has also been found to involve common iliac, common femoral or profunda femoris arteries.<sup>32</sup> It is frequently unilateral in distribution, with the left

side being affected more often than the right. Some investigators have found lesions to be only slightly more common on the left (52%),<sup>22</sup> whilst others have suggested there may be a unilateral, left sided lesion in 80–90% of patients.<sup>23,24</sup> Less than 15% of patients have been found to have bilateral flow-limitation at time of presentation.<sup>24,33,34</sup>

### Aetiology

Many factors have been implicated in the development of endofibrosis and iliac kinking. Whilst the majority of these are local mechanical factors, systemic factors may also be involved.

#### Position of cyclists

Since these conditions are most often observed in cyclists and speed skaters, it has been suggested that physical position may contribute to their development. The extreme aerodynamic position used by these athletes results in hyperflexion at the hip joint and may cause repetitive stretching and deformation of the iliac arteries, stimulating endofibrotic change.<sup>19</sup>

#### Psoas hypertrophy

Stretching of the external iliac artery may be exacerbated by psoas muscle hypertrophy and cyclists with the condition have been found to have asymmetrical thigh development, with thigh circumference up to 3 cm greater on the affected side.<sup>1,31</sup> Hypertrophy of the psoas muscle may increase any arterial displacement caused by hyperflexion of the hip,<sup>19</sup> thereby exacerbating kinking and increasing the mechanical stresses that may lead to endofibrosis.

#### Arterial fixation

Repetitive hyperflexion of the hip may also cause mechanical trauma to the iliac vessels because of their anatomical fixation to surrounding tissues. Fascia and collateral branches immobilize the iliofemoral vessels as they pass beneath the inguinal ligament and muscular branches to psoas major (which may enlarge or even become duplicated with intensive muscle activity) tether the central portion of the vessel.<sup>35,36</sup> This prevents the external iliac artery from moving freely during exercise, making kinking more acute and increasing the traumatic impact of hyperflexion.

#### Excessive vessel length

Whilst arterial kinking may be caused by fixation of the external iliac artery, it may also be the result of abnormally long iliac vessels. Elongation of the artery makes the vessel more tortuous and increases the likelihood of kinking during hip flexion and several studies have demonstrated a subgroup of symptomatic cyclists that have elongated external iliac arteries.<sup>1,25</sup> In this subgroup, the ratio of vessel length to straight-line distance of the external iliac artery was shown to be greater than 1.25.<sup>20</sup> These patients are unlikely to benefit from simple surgical release as kinking is caused by excess arterial length rather than fixation.

Most authors suggest that kinking stimulates endofibrosis, which in turn leads to arterial stenosis.<sup>37</sup> However, arterial kinking may be sufficient to cause a 'functional' flow restriction even when no significant endofibrotic lesion is apparent.<sup>38</sup> This is supported by Schep et al., who demonstrated that peak systolic velocities were significantly increased with manoeuvres that provoked kinking.<sup>39</sup>

Whilst there may be a link between vessel length and flow limitation, clear causation is hard to establish. Though the iliac

arteries were significantly longer in symptomatic legs than in the reference legs (which were a control group of completely symptom free athletes), there was no significant difference in vessel length between the symptomatic and asymptomatic legs of any one patient. This suggests that whilst excess vessel length may be contributory in flow limitation, it may not be sufficient to cause symptoms in the absence of other pathology.

#### Systemic factors

In addition to the local factors already mentioned, some investigators have suggested that metabolic abnormalities may also be contributory. Feugier and Chevalier<sup>22</sup> found that nearly 75% of patients who had undergone intervention for symptomatic endofibrosis displayed abnormalities in methionine metabolism following systemic doses of sulphur amino acids. Whilst this may be an incidental association rather than a predisposing factor, it undoubtedly warrants further investigation. Metabolic factors have also been implicated by Wright et al., who demonstrated endothelial dysfunction in a diabetic marathon runner, with subsequent reduction in flow-mediated arterial dilatation during exercise.<sup>40</sup> It is therefore conceivable that other metabolic disorders could cause functional stenoses in non-diabetic patients by inhibiting endothelium-dependent dilatation.

Unusually high cardiac output or intense physical activity may also cause local endothelial dysfunction, though the evidence for this is not strong.<sup>41–44</sup>

### Symptoms

Symptoms are generally unilateral and only become apparent at near-maximal exercise. Cramp is the predominant symptom and most report a feeling of swelling, numbness or pain that develops in the calf, thigh or buttock on the affected side. Some patients also experience weakness in the affected limb and exercise is often halted by the onset of numbness or paralysis. However, the history may be very non-specific, leading to significant delay in diagnosis. Delays of 12–41 months have been described between onset of symptoms and correct diagnosis. Paradoxically, this delay is greater in professionals than in amateur athletes.<sup>23,45</sup>

Physical examination is often unremarkable at rest and all pulses are typically present. A bruit may be audible over the iliac or femoral vessels, especially after exercise<sup>46</sup> or with the hip in flexion.<sup>1</sup> Only very rarely do patients present with signs and symptoms of subacute ischaemia in the affected limb. This is usually the result of localized dissection and arterial occlusion.<sup>22,34</sup>

### Diagnosis

The diagnostic difficulty caused by relatively non-specific symptoms has previously led to the development of a detailed questionnaire to help discriminate vascular from non-vascular causes of leg pain in these athletes.<sup>24</sup> This questionnaire assesses such areas as duration of symptoms, number of affected muscle groups and risk factors for vascular disease. In terms of patients' symptoms, the findings most likely to indicate a vascular cause were: 'disappearance of complaints in less than five minutes' and 'involvement of more than three muscle areas'. Combining these two points of history with examination findings of an audible femoral bruit (with the hip in extension) and normal back mobility allowed correct identification of a vascular cause in 79% of cases<sup>24,28</sup> (Table 2).

When history and examination are not suggestive of a vascular cause, musculoskeletal causes of the patients symptoms must be

**Table 2**  
Diagnostic accuracy of specific history and examination.

Test variable	Sensitivity	Specificity	Positive predictive value	Negative predictive value	Number of legs tested	Positive likelihood ratio	Negative likelihood ratio	SIGN level of evidence	Reference
Disappearance of complaint in less than 5 min of rest	0.97	0.29	0.70	0.83	92	1.36	0.10	2+	28
Symptoms in >3 muscles (out of 6)	0.48	0.94	0.93	0.52	92	8.0	0.55	2+	28
Femoral bruit (with hip flexed)	0.76	0.65	0.79	0.61	92	2.17	0.37	2+	28
Femoral bruit (with hip extended)	0.36	0.94	0.91	0.46	92	6	0.68	2+	28
Normal back mobility	0.91	0.29	0.69	0.67	92	1.28	0.31	2+	28

excluded and patients should be referred for detailed orthopaedic and neurological assessment.

Sensitivity and specificity of physical examination can be significantly improved with a variety of provocative exercise tests (Table 3). Resting ankle-brachial pressure index (ABPI) is usually normal, but when ABPI is recorded within 5 min of ceasing maximal exercise, it may be possible to identify endofibrotic flow-limitation with sensitivity and specificity of up to 100%.<sup>47–50</sup> In patients with unilateral symptoms, a between-leg ABPI difference of more than 0.18 during the first minute of recovery is also a significant indicator of an arterial lesion.<sup>51</sup> For those with subtle flow limitations (possibly caused by kinking rather than endofibrosis) a between-leg difference of more than 23 mmHg in absolute ankle systolic blood pressure can identify a vascular pathology with a sensitivity of 73% and specificity of 95%.<sup>24,28</sup> These results were achieved by measuring the ABPI with the hips flexed. Overall, though the precise diagnostic values were different in these various studies, there is clear agreement that ABPI measurement can be highly discriminatory when performed in the early post-exercise period.

Whilst Doppler waveforms are often found to be normal other than at extremes of exercise,<sup>16</sup> ultrasound measurement of peak systolic velocity (PSV) may be highly sensitive for endofibrotic stenosis. On examining symptomatic limbs, Schep et al. found PSV to be significantly higher than in reference limbs. This difference was accentuated by provocative manoeuvres such as hip flexion, isometric psoas contraction or exercise and allowed identification of both arterial kinking and intravascular lesions.<sup>28,39</sup>

In addition to allowing Doppler assessment of flow abnormalities, duplex ultrasonography can also be used to assess the anatomical abnormalities of endofibrosis or kinking (Table 4). In the study by Schep et al., ultrasonography identified external iliac kinking in 39% of symptomatic limbs compared to 11% in asymptomatic limbs and 0% in the reference group. Furthermore, intravascular lesions were identified in 61% of symptomatic legs compared to only 9% in asymptomatic legs. Ultimately, after assessing each patient in flexion, extension, with psoas contraction

and after exercise, duplex ultrasonography was able to demonstrate abnormalities (i.e. kinks or intravascular lesions) in the external iliac artery in 82% of symptomatic legs.<sup>39</sup> Others have used post-operative histology to confirm that Duplex ultrasound can identify intravascular lesions with a sensitivity of 86%.<sup>52</sup> However, this high level of sensitivity is dependent upon having a preselected patient population with relatively severe disease. Therefore, in studies that included patients with less marked symptoms (such as those of Schep et al.), sensitivity was much lower.<sup>24</sup>

Furthermore, ultrasound is highly user dependent and may have very poor sensitivity for common iliac artery kinking, since this usually occurs in a frontal plane, rendering it very hard to visualize with conventional ultrasound.<sup>38</sup>

Given the limitations of ultrasonography, static magnetic resonance angiography (MRA), is also of use in the assessment of iliac flow limitation.<sup>38,53</sup> This must be performed with the hips flexed as even elongated iliac arteries do not tend to kink with the hip in extension. In addition to identifying arterial kinks not seen with ultrasound, MRA allows detailed assessment of iliac artery length and clarifies which patients may benefit from surgical shortening of the artery. Nonetheless, MRA should still be used in conjunction with Duplex ultrasound since movement artefact can be substantial: Altered flow-dynamics within a kinked vessel cause significant beat-to-beat movement of the artery itself, reducing MRA sensitivity for intravascular lesions.

Whilst static digital subtraction angiography (DSA) has long been considered the gold standard for assessment of flow-limiting atherosclerosis, its role in imaging endofibrotic lesions has been less clear. Whilst its reported accuracy in identifying intravascular lesions has varied widely,<sup>23,26</sup> it may be useful in identifying both number and position of any tethering psoas arteries and helping to guide treatment.<sup>23</sup> It is most helpful when images are captured in multiple planes and with the hip in both flexion and extension. It also allows measurement of the pressure gradient across any segment of artery thought to be endofibrotic. This pressure gradient may be absent at rest but become quite significant following intra-arterial administration of vasodilators.<sup>46,54,55</sup> This

**Table 3**  
Diagnostic accuracy of post-exercise ankle pressures.

Test variable	Sensitivity	Specificity	Positive predictive value	Negative predictive value	Number of limbs tested	SIGN level of evidence	Reference
Inter-ankle pressure difference >23 mmHg at 1 min after exercise (hips flexed)	0.73	0.95	0.97	0.61	92	2+	28
Reduced ABPI in affected leg during first 5 min post-exercise (patient reclining)	1.0	1.0	–	–	36	2–	49
ABPI <0.66 at 1 min after max exercise (patient recumbent)	0.90	0.86	–	–	156	2+	50
ABPI <0.48 1 min after max exercise (patient supine)	0.80	1.0	–	–	75	2–	47
Inter-ankle pressure difference >22 mmHg during first 4 min after exercise (patient supine)	0.93	0.93	0.93	0.93	168	2+	48
Inter-ankle ABPI difference >0.1 during first 4 min after exercise (patient supine)	0.90	0.95	0.95	0.90	168	2+	48
Inter-ankle ABPI difference >0.18 1 min after exercise (patient supine)	–	–	–	–	–	2+	51

**Table 4**  
Diagnostic accuracy of specific imaging modalities.

Test variable	Sensitivity	Specificity	Number of limbs tested	SIGN level of evidence	Reference
<i>Detection of intra-arterial lesion</i>					
USS identification of stenosis	0.84 (EIA) 0.13 (CIA)	– (EIA) 0.67 (CIA)	14	2+	23
Doppler USS identification of intra-arterial lesion	0.61	0.93	92	2+	28
USS identification of endofibrosis	0.78	0.80	84	2+	52
DSA identification of stenosis	0.54 (EIA) 0.13 (CIA)	– (EIA) 1.0 (CIA)	14	2+	23
<i>Detection of arterial elongation/kinking</i>					
USS identification of elongated external iliac artery	0.86	0.57	14	2+	23
Doppler USS to identify kinking	0.39	1.0	92	2+	28
DSA identification of elongated external iliac artery	0.57	1.0	14	2+	23
MRA identification of kinking (with hip flexed)	– (EIA) – (CIA)	0.91 (EIA) 0.97 (CIA)	78	2+	38
<i>Detection of arterial tethering</i>					
USS identification of tethering psoas artery	0.86	0.57	14	2+	23
DSA identification of tethering psoas artery	0.57	1.0	14	2+	23

demonstrates that the arterial segment is unable to respond to prodilatory stimuli in the normal way and suggests it may cause flow limitation during exercise. Additionally, use of an intra-arterial catheter may potentially allow diagnostic sampling of the suspected lesion using a directional atherectomy device, though this is not generally recommended practice.<sup>46</sup>

CT-angiography has occasionally been used and is likely to become increasingly popular as CT resolution and 3D reconstruction improve. Though it exposes the patient to additional radiation and has not yet been shown to offer any diagnostic advantage over MRA combined with Duplex ultrasonography,<sup>32,34</sup> it may ultimately be more accessible in most vascular units.

Only one paper described using intravascular ultrasound (IVUS) in the assessment of endofibrosis. Lomis et al. report a single case in which a significant endofibrotic lesion was readily identified by IVUS despite being almost indiscernible with DSA or measurement of trans-lesional pressure gradient.<sup>56</sup> This lesion was responsible for a 30% reduction in luminal diameter compared to the contralateral side and highlights the poor sensitivity of these other investigations. Similarly, some groups have reported that near infrared spectroscopy (NIRS) may be useful in identifying patients with decreased thigh muscle perfusion and that reduced power in the affected limb (as measured by cycle ergometer crank-torque) may be a useful surrogate for poor iliac flow.<sup>57,58</sup> Larger, prospective studies are undoubtedly needed to establish the true efficacy of all of these techniques.

## Management

Since the development of endofibrosis and kinking is clearly multifactorial, management may involve a variety of treatment modalities depending on the relative contribution of each of these factors (Fig. 2).

Conservative measures should be used prior to any surgical intervention and recreational athletes should consider changing to a sport that does not involve extreme hip flexion. Atherosclerotic risk factors should be addressed according to standard guidelines, but there are no reports of specific medical therapies for iliac endofibrosis. Though long-term outcomes have yet to be established, it has been suggested that untreated stenosis may predispose these patients to atherosclerosis in later life.<sup>25</sup>

Cyclists should be advised to reduce the amount of time spent cycling and to raise the cycle handlebars or bring the saddle position forward to minimize hip flexion. Pulling upwards on the pedals should also be avoided in order to reduce psoas hypertrophy.

However, these basic measures often fail to relieve symptoms and whilst they may be acceptable for recreational cyclists, they may not be realistic for professional athletes.

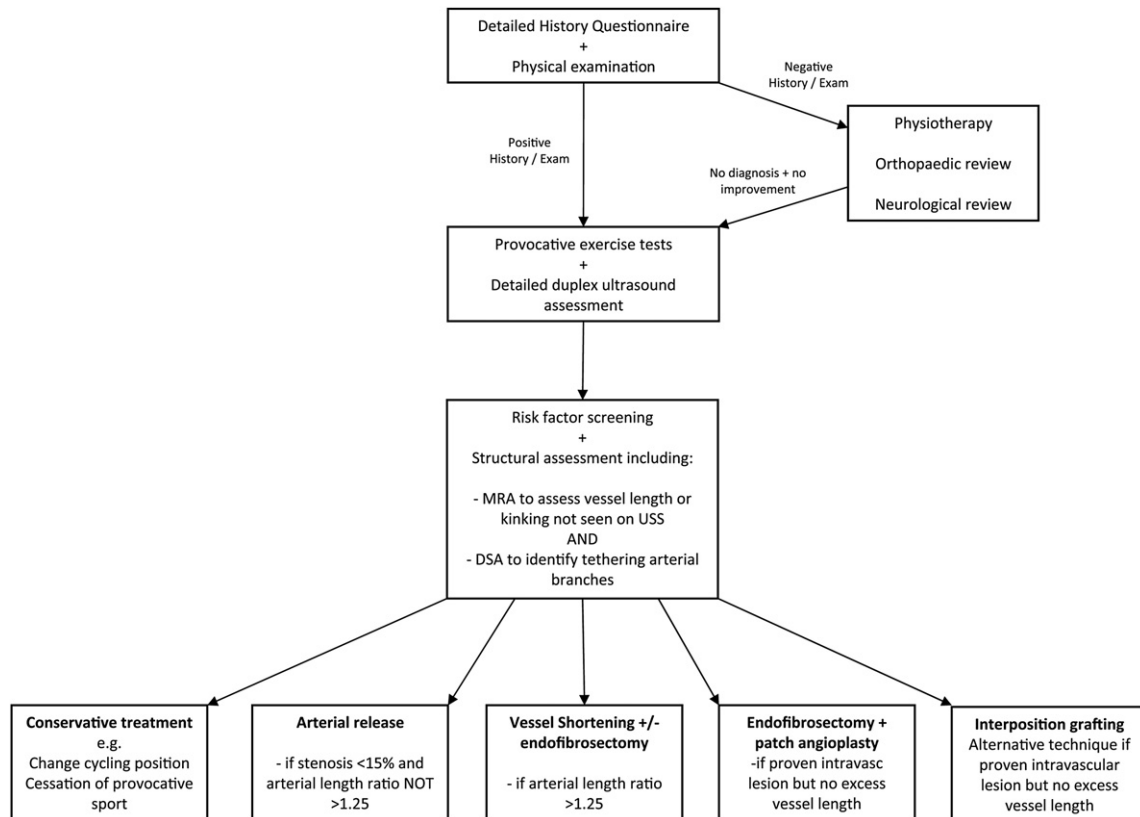
Though there is some evidence that endofibrotic lesions may stabilize when intensive training is stopped,<sup>33</sup> surgery is likely to be necessary for patients that have incapacitating symptoms or wish to continue the provocative activity.

Angioplasty is not effective in treating endofibrosis. A small number of case reports and case-series have demonstrated good short-term functional outcomes, though patients have all experienced recurrence of symptoms within eight weeks.<sup>54,55</sup> Only one report identified in this review described longer-lasting improvement in symptoms following angioplasty.<sup>16</sup> Furthermore, angioplasty fails to address any underlying abnormality of vessel length<sup>22</sup> and may potentially result in dissection of the endofibrotic segment.<sup>22,41</sup>

Endoluminal stent placement would also seem to be an inappropriate treatment option in endofibrosis as the mechanical forces inherent to the condition may cause stent migration or fracture with resultant arterial damage. Stents may also lead to intimal hyperplasia.<sup>45</sup> Nonetheless, Maree et al. did achieve good short-term results when treating a 46 yr old symptomatic runner with this technique. At three month follow-up the patient was symptom free and had returned to full physical activity.<sup>46</sup> Venstermanns et al. also described stenting an endofibrotic iliac lesion in a 25 yr old cyclist, but outcome was not reported.<sup>32</sup> Notably, both of the patients that had relatively good outcome after angioplasty or stenting were endurance runners rather than cyclists.

In the absence of any reliable endovascular technique, open surgical correction remains the mainstay of treatment. Schep et al. demonstrated that release of restrictive fibrous tissue and division of any tethering branches of the external iliac artery (especially the branch to psoas if present) can be beneficial in patients with abnormal vessel fixation and proven arterial kinking. An advantage of this procedure is that it can be performed through a small suprainguinal incision. Furthermore, the iliac vessels are left intact, which may mean subsequent complications are less likely.<sup>45</sup> However, patients must be selected carefully to ensure that arterial release is not attempted in isolation for patients who also have significant endoluminal narrowing. Indeed, Alimi et al. found arterial release to be useful in patients with demonstrated arterial kinking, but only as an adjunct to more formal iliac artery reconstruction.<sup>23</sup>

When diagnostic imaging has demonstrated significant arterial elongation this procedure may not be sufficient,<sup>45</sup> since hip flexion



**Figure 2.** Proposed strategy for the investigation and management of endofibrosis.

is likely to result in kinking of the artery even if the vessel is not abnormally tethered. It is also likely to be ineffective if there is an endofibrotic lesion narrowing the lumen by more than 25%. For this reason, some groups have advocated arterial shortening, with endarterectomy of the remaining artery as necessary.<sup>1,25</sup> This technique may be associated with fewer complications than other reconstructive techniques, since it involves only a single anastomosis and no patching is needed. However, there is no clear evidence to support this view.

Where there is fibrotic stenosis but arterial length is within the normal range, a more conventional endarterectomy (also termed endofibrossectomy) may be performed. Most groups then achieve closure of the arteriotomy using vein patch angioplasty, though primary closure and synthetic patch angioplasty have also been described.<sup>26,59–61</sup>

Some authors have favoured complete resection of the stenosed segment and subsequent replacement with a saphenous vein interposition graft.<sup>23</sup> Others have described using PTFE or Gore-Tex grafts when the saphenous vein was too small to be used, but no follow-up data was presented for any of these interposition techniques.<sup>31,34</sup>

## Outcome

Though most authors have not published long-term outcomes following intervention for iliac endofibrosis, Chevalier's group (Lyon, France) presented follow-up data from their experience of over three hundred patients<sup>22</sup> (Table 5). In this cohort of symptomatic athletes, 68% were treated with endofibrossectomy, 31% were treated with bypass and 1% underwent angioplasty. Though outcomes were not reported in relation to each specific intervention, less than 3% of the total patient group suffered any complication (though the severity of these complications was not clear).

Mean delay before returning to sport was 2.84 months and 99% had returned to some level of sporting activity during the mean follow-up of 53 months. 1.5% suffered persistence of pain during exercise. Schep et al. have also published outcomes from a series of 24 patients, of which 23 underwent arterial release and 1 had 'vascular reconstruction' (for an elongated iliac artery). At mean follow-up of 9 months, all athletes had improved subjectively and 12 (52%) were symptom free. However, eight athletes (35%) were not completely symptom free, but able to resume competition at pre-morbid level and three were not sufficiently improved to return to competition<sup>45</sup> (Table 5).

Though the overall complication rate is perhaps low, the nature of these procedures means that when complications do arise they may be catastrophic. For this reason, surgical intervention – particularly procedures involving reconstruction of the iliac vessels – should only be undertaken after patients have tried conservative measures and carefully considered changing sport.

## Discussion

With the exception of a few major groups, most evidence to date has been derived from isolated case reports and small case-series. In addition to endofibrosis, the issue of arterial kinking has been dealt within some detail here since it is heavily implicated in the genesis of endofibrosis. Though Schep et al. have suggested that iliac kinking alone may cause flow limitation, they have also shown that 48% of patients only experience a moderate improvement in symptoms following surgical release of an abnormally tethered iliac artery. This would suggest that in these patients it may be the additive effect of kinking *and* vessel stenosis that ultimately lead to flow limitation and development of symptoms.

Though it seems clear that there is a relationship between kinking and endofibrosis, the exact nature of this relationship

**Table 5**  
Outcomes following intervention for endofibrosis.

Intervention	No. of limbs treated with each intervention	Total no. of patients	Complications	Outcome (across all types of intervention)	Mean follow-up (months)	SIGN level of evidence	Reference
Endofibrosectomy and arterial shortening	237	334	9 (unspecified)	332 returned to sport	53	3	22
Arterial bypass with saphenous vein	110			5 had persistent symptoms			
Percutaneous transluminal angioplasty	3			Mean delay before return to sport 2.84 months			
Endofibrosectomy and arterial shortening	24	23	0	All patients returned to competition	–	3	25
Arterial release	23	24	0	12 (52%) were symptom free 8 (35%) had some symptoms but were able to return to competition at previous level 3 (9%) were improved but had symptoms that prevented return to previous level of competition 1 – no explicit outcome given	9 (range 4–36)	3	45
Vascular reconstruction	1						
Endofibrosectomy and vein patch angioplasty	11	13	1 graft occlusion 1 iliac haematoma	12 limbs had no residual symptoms	14.4 (range 1–64)	3	23
Saphenous vein interposition grafting	3		3 restenosis (requiring repeat intervention)	2 limbs had diminished symptoms 10 of the patients returned to competition 3 patients chose not to return to sport			
Vein patch angioplasty (without endofibrosectomy)	6	6	0	5 had no residual symptoms 1 lost to follow-up	– (range 18–70)	3	37

requires further clarification. In particular, focused investigation is necessary to identify the subgroup of patients in which arterial kinking may cause symptoms in the absence of any significant intravascular lesion. Wider use of intravascular ultrasound may provide the answer to this problem and help clarify the most appropriate intervention for each patient subgroup.

From the studies detailed above, it is clear that whilst there is general consensus on potentially useful imaging techniques and treatment strategies, there is no well-established algorithm for the investigation and management of these patients. In addition, certain diagnostic tools such as IVUS, crank-torque measurement and NIRS still warrant further evaluation. The data presented here suggests that neither clinical evaluation nor any single form of imaging is sufficient to independently identify iliac endofibrosis. However, using a number of these in combination can significantly improve sensitivity and specificity (Table 2).<sup>28</sup>

Unfortunately, since there is no 'gold-standard' imaging modality that can definitively identify endofibrosis or arterial kinking, the true prevalence of these conditions – particularly in asymptomatic athletes – remains uncertain. The reported sensitivity and specificity of the different imaging techniques should be viewed with this in mind. Furthermore, whilst endofibrosis can be histologically proven at operation,<sup>22,23,47,48</sup> flow-restrictions due to arterial kinking are much more difficult to verify since these are often functional (rather than anatomical) abnormalities. The minor intra-arterial lesions that may coexist with arterial kinking are also difficult to prove since these patients may simply undergo arterial release, without the arterial resection necessary for formal histological diagnosis.<sup>45</sup>

By considering a diagnosis of iliac flow limitation when patients present with these symptoms, primary care physicians can use a discriminatory history and physical examination to identify nearly 80% of those with iliac flow limitation.<sup>28</sup> These patients can then be referred for duplex imaging (including ABPI, inter ankle pressure difference, PSV and assessment of kinking). Having established that flow-limitation is present, more detailed imaging

can then be used to characterize the lesion. MRA allows assessment of vessel length and intravascular narrowing (including common, internal and external iliac vessels), whilst DSA may be used to identify tethering arterial branches.<sup>23</sup> CT-angiography (with 3D reconstruction) may subsequently supersede these modalities but there is currently insufficient evidence to support this.

Surgical intervention should be considered whenever patients have demonstrated arterial kinking or intravascular lesion and conservative measures have failed (Fig. 2). Endovascular techniques should be avoided since long-term outcomes have been poor. Surgical release should only be used in isolation when there is minimal luminal stenosis (<15%), but may also be used to good effect in combination with arterial reconstruction. If imaging has demonstrated significant vessel elongation, arterial shortening should be performed with endofibrosectomy as necessary. When the iliac artery is shown to be of normal length but there is significant endofibrotic stenosis, endofibrosectomy and patch-plasty should be performed. Interposition grafting (with vein) is also an option for these patients.<sup>23</sup> Use of prosthetic materials should be avoided.<sup>54</sup>

Though surgery has certainly allowed many athletes to return to elite sport, there is very little information on long-term outcomes or the relative benefits of the different operative techniques, since no comparative studies have been undertaken. The proposed treatment algorithm should be viewed in this context.

However, due to the nature and rarity of iliac endofibrosis and kinking, trials directly comparing interventions are impractical and case series (with possible establishment of a registry) are likely to remain the major source of evidence for treatment. By standardizing the approach taken by clinicians it should be possible to gather more uniform data and improve both diagnosis and management of these conditions.

## Conclusion

Whilst iliac flow limitation continues to gain increasing recognition amongst both athletes and healthcare professionals, it may



still go undiagnosed or be treated ineffectively. This is because when patients first present, the differential diagnosis is large and diagnostic tests for flow limitation lack sensitivity. Furthermore, the lack of consistent methodology and follow-up data has previously led to confusion about the best treatment strategy.

With the inclusion of tests that have been specifically developed for these patients, we now propose a unifying algorithm for diagnosis and management of iliac artery endofibrosis and kinking.

## Acknowledgements

The authors would like to acknowledge the contributory comments and assistance of Professor Y.O. Schumacher and Mr C. Edmundson.

## Conflict of Interest/Funding

None declared.

## References

- Chevalier JM, Enon B, Walder J, Barral X, Pillot J, Megret A, et al. Endofibrosis of the external iliac artery in bicycle racers: an unrecognized pathological state. *Ann Vasc Surg* 1986;1(3):297–303.
- Mosimann R, Walder J, Van Melle G. Stenotic intimal thickening of the external iliac artery: illness of the competition cyclist? Report of two cases. *Vasc Endovascular Surg* 1985;19(4):258–63.
- Moher D, Liberati A, Tetzlaff J, Altman DG, Group TP. Preferred reporting items for systematic reviews and meta-analyses: the PRISMA Statement. *Open Med* 2009:e123–30.
- von Elm E, Altman DG, Egger M, Pocock SJ, Gøtzsche PC, Vandenbroucke JP, et al. The Strengthening of Reporting of Observational Studies in Epidemiology (STROBE) statement: guidelines for reporting observational studies. *Lancet* 2007;1453–7.
- Whiting P, Rutjes AWS, Reitsma JB, Bossuyt PMM, Kleijnen J. The development of QUADAS: a tool for the quality assessment of studies of diagnostic accuracy included in systematic reviews. *BMC Med Res Methodol* 2003;25.
- SIGN. *SIGN 50: a guideline developer's handbook*. Scottish Intercollegiate Guidelines Network; 2008.
- Bucci F, Ottaviani N, Plagnol P. Acute thrombosis of external iliac artery secondary to endofibrosis. *Ann Vasc Surg* 2011. 698.e5–7.
- Carmo G, Rosa A, Ministro A, Cunha ESd, Pestana C. Non-atherosclerotic lower limbs ischemia in young athletes. *Rev Port Cir Cardiorasc Vasc* 2008;157–61.
- Del Gallo G, Plissonnier D, Planet M, Peillon C, Testart J, Watelet J. Dissecting aneurysm of the external iliac artery. An unusual course of endofibrosis in an athlete. *J Mal Vasc* 1996;95–7.
- Guermazi M, Ghroubi S, Elleuch MH, Rodineau J. Endofibrose de l'artère iliaque externe chez un arbitre de football. [Endofibrosis of the external iliac artery in a soccer referee]. *Journal de traumatologie du sport* 2003;20(3):174–8.
- Hindryckx C, Rousseaux M, Vanderstraeten GG, van den Brande F. Endofibrosis of the external iliac artery: a cyclists' syndrome? A case report. *Eur J Phy Med Rehabil: Blackwell* 1996:126–7.
- Masmoudi S, Frikha I, Hadjicacem A, Yangui M, Mnif J, Elleuch H, et al. Clinical case of the month. Iliac artery endofibrosis in a soccer player. *Rev Med Liege* 2002;135–7.
- Monti M, Jaeger M, Guisan Y, Payot M, Mazzoni S. Diagnosis of peripheral arterial insufficiency in the amateur athlete with claudication and the detection of "the isolated iliac artery stenosis syndrome in young bicyclists with no risk factors" with the Doppler and rolling carpet tests. *Rev Med Suisse Romande* 1984;823–30.
- Paraf F, Petit B, Roux J, Bertin F, Laskar M, Labrousse F. External iliac artery endofibrosis of the cyclist. *Ann Pathol* 2000;232–4.
- Takach T, Kane P, Madjarov J, Holleman J, Nussbaum T, Robicsek F, et al. Arteriopathy in the high-performance athlete. *Tex Heart Inst J* 2006;33(4):482.
- Ford S, Rehman A, Bradbury A. External iliac endofibrosis in endurance athletes: a novel case in an endurance runner and a review of the literature. *Eur J Vasc Endovasc Surg* 2003;26(6):629–34.
- Speedy DB, Abraham P, Graham KJ, Charlesworth P. External iliac artery endofibrosis in a triathlete. *Clin J Sport Med* 2000;10(2):148–9.
- Bray AE, Lewis WA. Intermittent claudication in a professional rugby player. *J Vasc Surg* 1992;15(4):664–8.
- Bender MHM, Schep G, de Vries WR, Hoogveen AR, Wijn PFF. Sports-related flow limitations in the iliac arteries in endurance athletes: aetiology, diagnosis, treatment and future developments. *Sports Med* 2004;34(7):427–42.
- Schep G, Kaandorp D. Excessive length of iliac arteries in athletes with flow limitations measured by magnetic resonance angiography. *Med Sci Sports Exerc* 2002;34(3):385.
- Khaira HS, Awad RW, Aluwihare N, Shearman CP. External iliac artery stenosis in a young body builder. *Eur J Vasc Endovasc Surg* 1996;11(4):499–501.
- Feugier P, Chevalier J. Endofibrosis of the iliac arteries: an underestimated problem. *Acta Chir Belg* 2004;104(6):635–40.
- Alimi Y, Accrocca F, Barthclemey P, Hartung O, Dubuc M, Boufi M. Comparison between duplex scanning and angiographic findings in the evaluation of functional iliac obstruction in top endurance athletes. *Eur J Vasc Endovasc Surg* 2004;28(5):513–9.
- Schep G, Schmikli SL, Bender MH, Mosterd WL, Hammacher ER, Wijn PF. Recognising vascular causes of leg complaints in endurance athletes. Part 1: validation of a decision algorithm. *Int J Sports Med* 2002;23(5):313–21.
- Rousselet MC, Saint-Andre JP, L'Hoste P, Enon B, Megret A, Chevalier JM. Stenotic intimal thickening of the external iliac artery in competition cyclists. *Hum Pathol* 1990;21(5):524–9.
- Kral C, Han D, Edwards W, Spittell P, Tazelaar H, Cherry K. Obstructive external iliac arteriopathy in avid bicyclists: new and variable histopathologic features in four women. *J Vasc Surg* 2002;36(3):565–70.
- Vink A, Bender M, Schep G, van Wichen D, de Weger R, Pasterkamp G, et al. Histopathological comparison between endofibrosis of the high-performance cyclist and atherosclerosis in the external iliac artery. *J Vasc Surg* 2008;48(6):1458–63.
- Schep G, Bender MH, Schmikli SL, Mosterd WL, Hammacher ER, Scheltinga M, et al. Recognising vascular causes of leg complaints in endurance athletes. Part 2: the value of patient history, physical examination, cycling exercise test and echo-Doppler examination. *Int J Sports Med* 2002;23(5):322–8.
- Perdu J, Boutouyrie P, Bourgain C, Stern N, Laloux B, Bozec E, et al. Inheritance of arterial lesions in renal fibromuscular dysplasia. *J Hum Hypertens* 2007;21(5):393–400.
- Holden A, Merrilees S, Mitchell N, Hill A. Magnetic resonance imaging of popliteal artery pathologies. *Eur J Radiol* 2008;67(1):159–68.
- Scavée V, Stainier L, Deltombe T, Theys S, Delos M, Trigaux J-P, et al. External iliac artery endofibrosis: a new possible predisposing factor. *J Vasc Surg* 2003;38(1):180–2.
- Venstermans C, Gielen JL, Salgado R, Bouquillon P, Lauwers J. Endofibrosis of the external iliac artery. *JBR-BTR* 2009;92(3):184–5.
- Abraham P, Chevalier JM, Saumet JL. External iliac artery endofibrosis: a 40-year course. *J Sports Med Phys Fitness* 1997;37(4):297–300.
- Willson TD, Revesz E, Podbielski FJ, Blecha MJ. External iliac artery dissection secondary to endofibrosis in a cyclist. *J Vasc Surg* 2010;52(1):219–21.
- Shankar V, Roskell D, Darby C. Iliac artery syndrome: successful outcome after endarterectomy and vein patch angioplasty. *EJVES Extra* 2006;(11):107–9.
- Pillet J, Chevalier JM, Rasomanana D, Enon B, Mercier P, Lescaie F, et al. The principal artery of the psoas major muscle. *Surg Radiol Anat* 1989;11(1):33–6.
- Smith W, Olmsted K, Zieler E. Iliac artery endofibrosis in athletes: a case series. *JVU* 2008;32(4):193–9.
- Schep G, Kaandorp DW, Bender MH, Weerdenburg H, van Engeland S, Wijn PF. Magnetic resonance angiography used to detect kinking in the iliac arteries in endurance athletes with claudication. *Physiol Meas* 2001;22(3):475–87.
- Schep G, Bender MH, Schmikli SL, Wijn PF. Color Doppler used to detect kinking and intravascular lesions in the iliac arteries in endurance athletes with claudication. *Eur J Ultrasound* 2001;14(2–3):129–40.
- Wright IA, Pugh ND, Goodfellow J, Wood AM, Lane IF, Fraser AG. Dynamic obstruction of the external iliac artery in endurance athletes and its relationship to endothelial function: the case of a long distance runner. *Br J Sport Med* 1997;31(2):156–8.
- Cook P, Erdoes L, Selzer P, Rivera F, Palmaz J. Dissection of the external iliac artery in highly trained athletes. *J Vasc Surg* 1995;22(2):173–7.
- Bergholm R, Mäkimattila S, Valkonen M, Liu ML, Lahdenperä S, Taskinen MR, et al. Intense physical training decreases circulating antioxidants and endothelium-dependent vasodilatation in vivo. *Atherosclerosis* 1999;145(2):341–9.
- Abraham P, Saumet JL, Desvaux B, Fromy B. Can aerobic exercise training be hazardous to human vessels? *Circulation* 2000;102(20):E168.
- Goto C, Higashi Y, Kimura M, Noma K, Hara K, Nakagawa K, et al. Effect of different intensities of exercise on endothelium-dependent vasodilation in humans: role of endothelium-dependent nitric oxide and oxidative stress. *Circulation* 2003;108(5):530–5.
- Schep G, Bender M, van de Tempel G, Wijn P, de Vries W, Eikelboom B. Detection and treatment of claudication due to functional iliac obstruction in top endurance athletes: a prospective study. *Lancet* 2002;359(9305):466–73.
- Maree AO, Ashequl Islam M, Snuderl M, Lamuraglia GM, Stone JR, Olmsted K, et al. External iliac artery endofibrosis in an amateur runner: hemodynamic, angiographic, histopathological evaluation and percutaneous revascularization. *Vasc Med* 2007;12(3):203–6.
- Bruneau A, Le Faucher A, Mahe G, Vielle B, Leftheriotis G, Abraham P. Endofibrosis in athletes: is a simple bedside exercise helpful or sufficient for the diagnosis? *Clin J Sport Med* 2009;19:282–6.
- Le Faucheur A, Noury-Desvaux B, Jaquinandi V, Louis Saumet J, Abraham P. Simultaneous arterial pressure recordings improve the detection of endofibrosis. *Med Sci Sports Exerc* 2006;38(11):1889–94.
- Fernandez-Garcia B, Alvarez-Fernandez J, Vega G. Diagnosing external iliac endofibrosis by postexercise ankle to arm index in cyclists. *Med Sci Sports Exerc* 2002;34(2):222.
- Abraham P, Bickert S, Vielle B, Chevalier J, Saumet J. Pressure measurements at rest and after heavy exercise to detect moderate arterial lesions in athletes. *J Vasc Surg* 2001;33(4):721–7.

- 51 Taylor A, George K. Ankle to brachial pressure index in normal subjects and trained cyclists with exercise-induced leg pain. *Med Sci Sports Exerc* 2001;**33**(11):1862.
- 52 Abraham P, Leftheriotis G, Bourre Y, Chevalier JM, Saumet JL. Echography of external iliac artery endofibrosis in cyclists. *Am J Sports Med* 1993;**21**(6):861–3.
- 53 Lim CS, Gohel MS, Shepherd AC, Davies AH. Iliac artery compression in cyclists: mechanisms, diagnosis and treatment. *Eur J Vasc Endovasc Surg* 2009;**38**(2):180–6.
- 54 Giannoukas A, Berczi V, Anoop U, Cleveland T, Beard J, Gaines P. Endofibrosis of iliac arteries in high-performance athletes: diagnostic approach and minimally invasive endovascular treatment. *Cardiovasc Inter Rad* 2006;**29**(5):866–9.
- 55 Wijesinghe LD, Coughlin PA, Robertson I, Kessel D, Kent PJ, Kester RC. Cyclist's iliac syndrome: temporary relief by balloon angioplasty. *Br J Sports Med* 2001;**35**(1):70–1.
- 56 Lomis NN, Miller FJ, Whiting JH, Giuliano AW, Yoon HC. Exercise-induced external iliac artery intimal fibrosis: confirmation with intravascular ultrasound. *J Vasc Interv Radiol* 2000;**11**(1):51–3.
- 57 Van Beekvelt MC, Colier WN, Wevers RA, Van Engelen BG. Performance of near-infrared spectroscopy in measuring local O<sub>2</sub> consumption and blood flow in skeletal muscle. *J Appl Physiol* 2001;**90**(2):511–9.
- 58 Edmundson CJ. Torque profiles as a non-invasive diagnostic tool to identify arterial flow restrictions and assess changes in cycling position. In: BASES Biomechanics Interest Group Annual Conference. Liverpool John Moore's University, 2007.
- 59 Korsten-Reck U, Röcker K, Schmidt-Trucksäss A, Schumacher YO, Striegel H, Rimpler H, et al. External iliac artery occlusion in a young female cyclist. *J Sports Med Phys Fitness* 2007;**47**(1):91–5.
- 60 O'Ceallaigh P, Burns P, McLaughlin R, Leader M, Bouchier-Hayes D. Complete external iliac artery occlusion in a 34-year-old cyclist. *Eur J Vasc Endovasc Surg* 2002;**23**(4):376–7.
- 61 Wille J, de Jong J, Moll F. Endofibrosis of the external iliac artery in sportsmen clinical review and four new cases. *Vasc Endovasc Surg* 1998;**32**(4):323–8.